

**PATIENT**

Teddy Martinez

**SPECIES**

Canine

**BREED**

Fench Bulldog

**SEX**

MN

**AGE**

4 years

**WEIGHT**

13.9 kg

**INTERPRETED BY**

Remo Lobetti, BVSc,  
MMedVet (Med),  
PhD, Dipl. ECVIM

**IMAGING  
PERFORMED BY**

Seth Mitchell, DVM

**HOSPITAL NAME**

Treasure Coast  
Animal Emergency

**REFERRING VET**

**INVOICE**

303632

**DATE**

12/7/22

**PRESENTING CLINICAL SIGNS**

History: GI tract signs.

Physical Examination: N/A.

Urinalysis: N/A

CBC: N/A.

Serum Biochemistry: N/A.

Radiographic Findings: N/A.

**ULTRASONOGRAPHIC EXAMINATION OF THE ABDOMEN**

**Urinary System**

Full urinary bladder with a normal thickness and appearance of the wall. Normal anechoic urine with no sediment or uroliths evident.

Normal trigone area, proximal urethra, and iliac blood vessels.

Normal iliac lymph nodes. Ureters not visualized.

Normal renal size (left kidney 5 cm, right 5.9 cm), echogenic appearance, cortico-medullary differentiation, pelvis, and capsule.

**Reproductive System**

Small hypoechogenic prostate (1 cm).

**Adrenal Glands**

Normal position, echogenic appearance, shape, and size. Left 0.55 cm, right 0.65 cm

**Spleen**

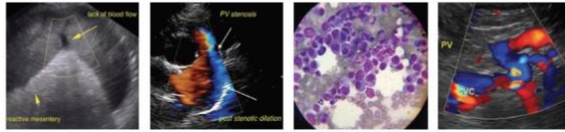
Normal size and echogenic appearance. Smooth homogenous parenchyma, regular curvilinear capsule, and normal vasculature. No evidence of inflammatory, neoplastic, infarction, or infiltrative changes noted.

**Liver**

Normal size, echogenic appearance, portal markings, and regular curvilinear capsule. No nodules or masses evident. Full gall bladder containing normal anechoic bile. Normal thickness and echogenic appearance of the gall bladder wall. Normal bile duct.

**Gastrointestinal**

Normal appearance of the gastro-esophageal junction, stomach, duodenum ileo-cecal junction, and colon with no loss of layering, normal wall thickness and peristaltic activity, and no distension of the lumen. Foreign body (1.4 x 3.2 cm) in the distal ileum with distension of the lumen. Normal thickness and appearance of the rest of the small intestine.



**PATIENT**

Teddy Martinez

**SPECIES**

Canine

**BREED**

Fench Bulldog

**SEX**

MN

**AGE**

4 years

**WEIGHT**

13.9 kg

**INTERPRETED BY**

Remo Lobetti, BVSc,  
MMedVet (Med),  
PhD, Dipl. ECVIM

**IMAGING  
PERFORMED BY**

Seth Mitchell, DVM

**HOSPITAL NAME**

Treasure Coast  
Animal Emergency

**REFERRING VET**

**INVOICE**

303632

**DATE**

12/7/22

***Pancreas***

Normal size and echogenic appearance. Normal echogenic appearance of the mesentery and fat surrounding the pancreas.

***Free Abdomen***

No mesenteric lymphadenomegaly.  
No ascites.

**ULTRASONOGRAPHIC FINDINGS**

Primary findings:

- Small intestinal foreign body.

Secondary findings:

- None.

**INTERPRETATION OF THE FINDINGS & FURTHER RECOMMENDATIONS IMAGES**

Further assessment/therapy would be laparotomy.



**PATIENT**

Teddy Martinez

**SPECIES**

Canine

**BREED**

Fench Bulldog

**SEX**

MN

**AGE**

4 years

**WEIGHT**

13.9 kg

**INTERPRETED BY**

Remo Lobetti, BVSc,  
MMedVet (Med),  
PhD, Dipl. ECVIM

**IMAGING PERFORMED BY**

Seth Mitchell, DVM

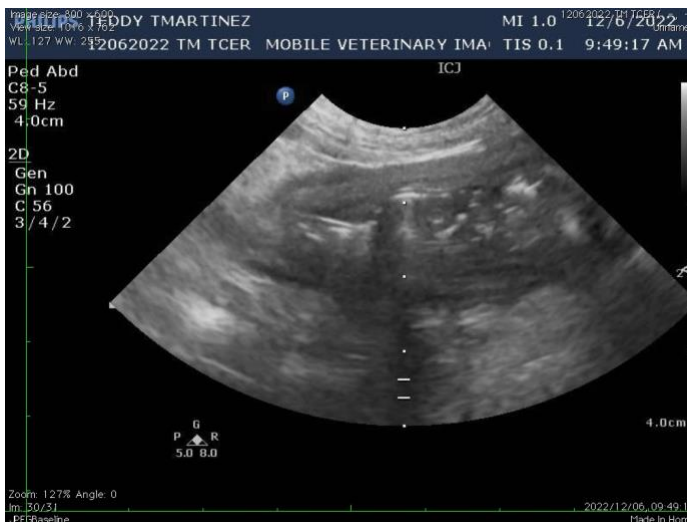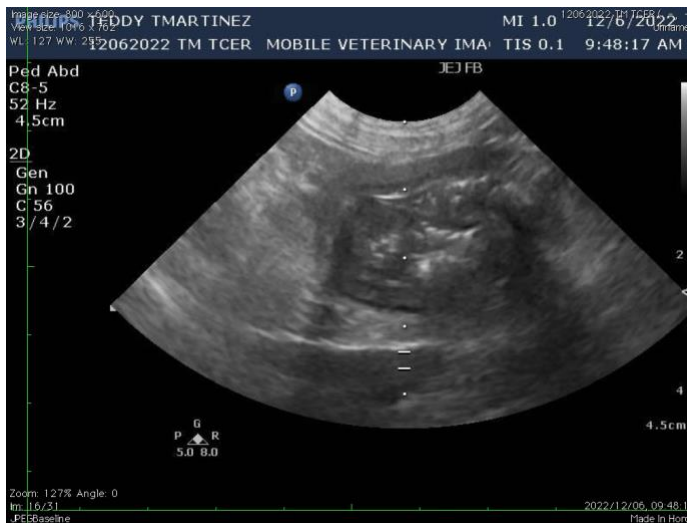**HOSPITAL NAME**

Treasure Coast  
Animal Emergency

**REFERRING VET**

**IMAGES**

Small intestine



The information and recommendations provided are based on the images presented by the referring veterinarian. No evaluation can be communicated regarding pathology that was not visible in the image/video clips provided.

Thank you for this referral. If the clinical or image interpretation does not parallel your findings or if I can be of any further assistance please contact me.

**Remo Lobetti, BVSc, MMedVet (Med), PhD, Dipl. ECVIM (Internal Medicine)**  
[rlobetti@mweb.co.za](mailto:rlobetti@mweb.co.za)

**INVOICE**

303632

**DATE**

12/7/22